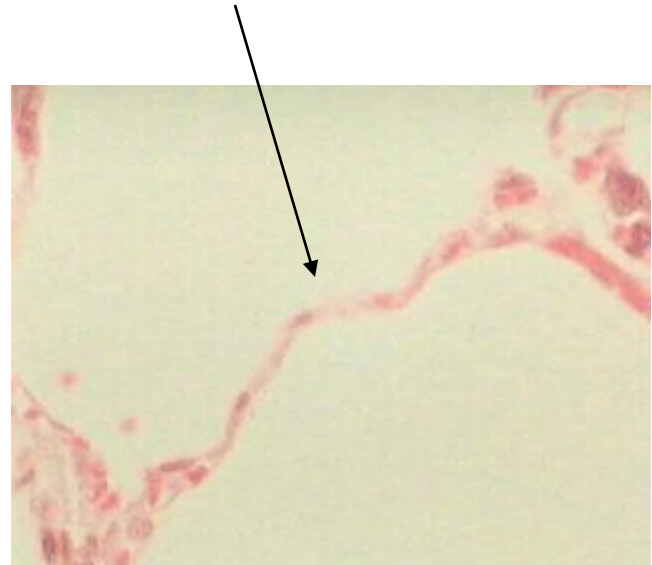
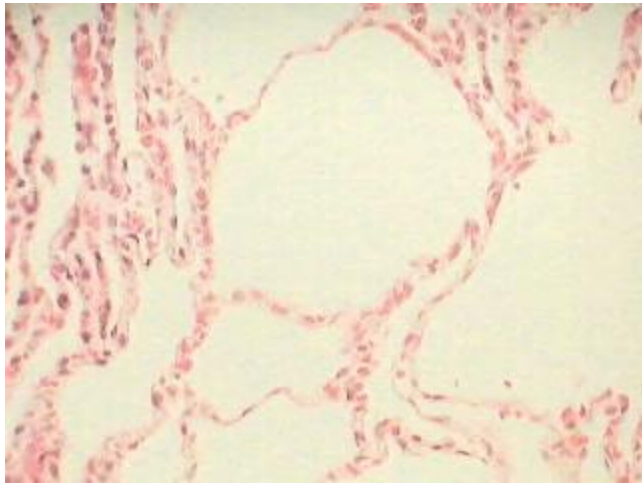

Slides for BIO 193

Lab Practical 1

Directions

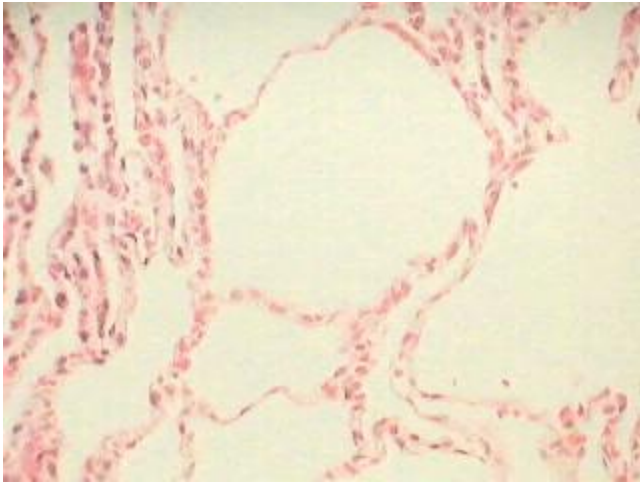
- For each question, think of the answer or write it down.
 - Click the forward button to advance to the answer screen.
 - Some questions will show two pictures of the same thing at different magnifications.
-

Question 1 – Name the tissue at the pointer.

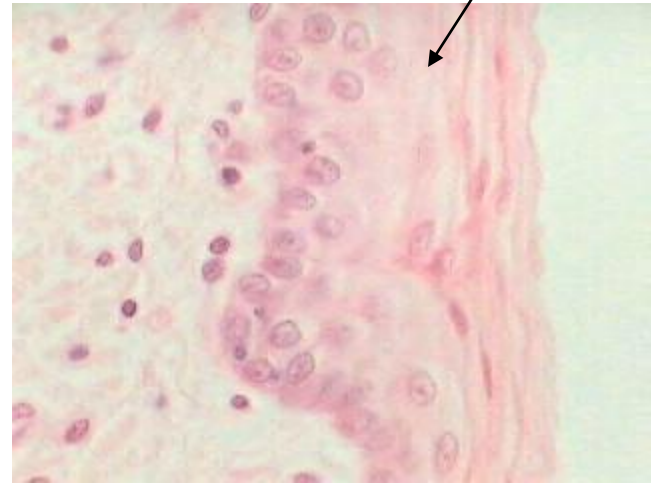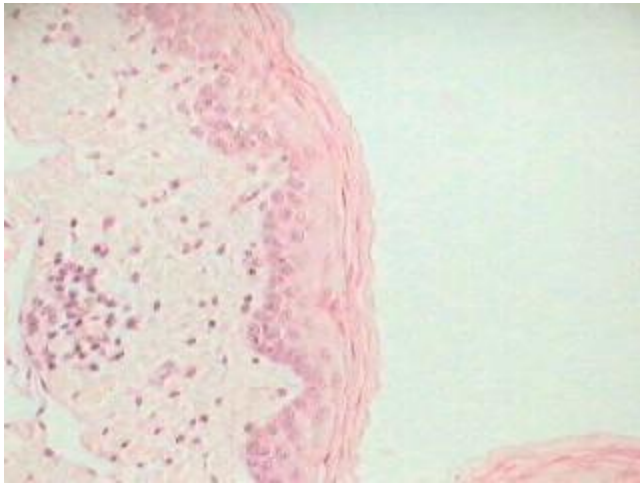


Question 1 Answer

Simple Squamous Epithelium

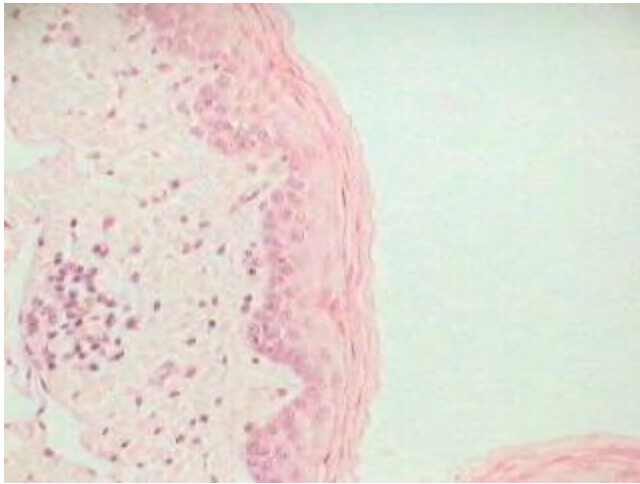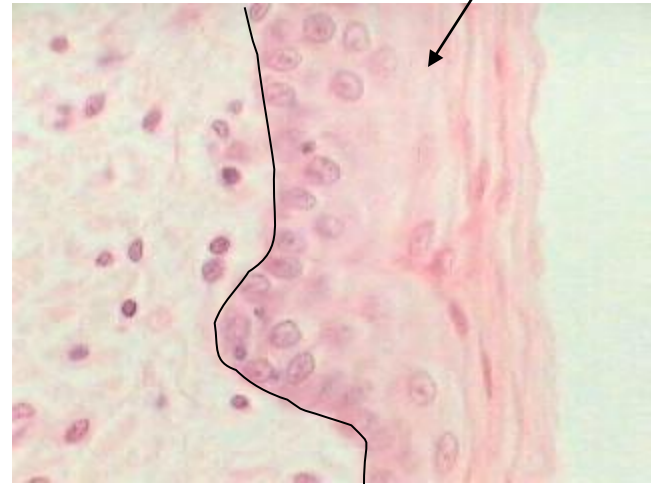


Question 2 – Name the tissue at the pointer.



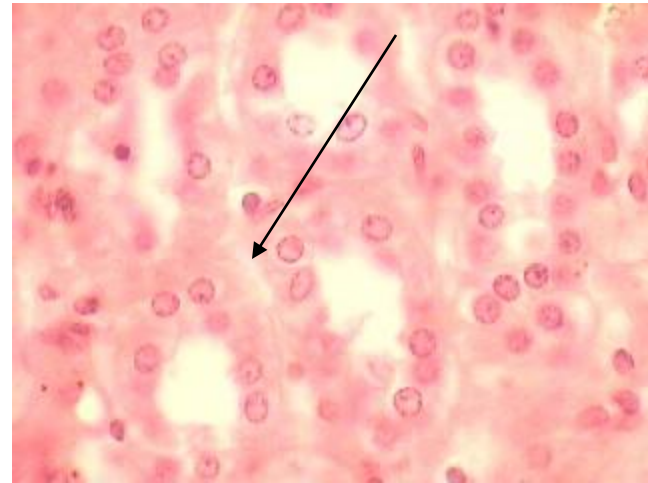
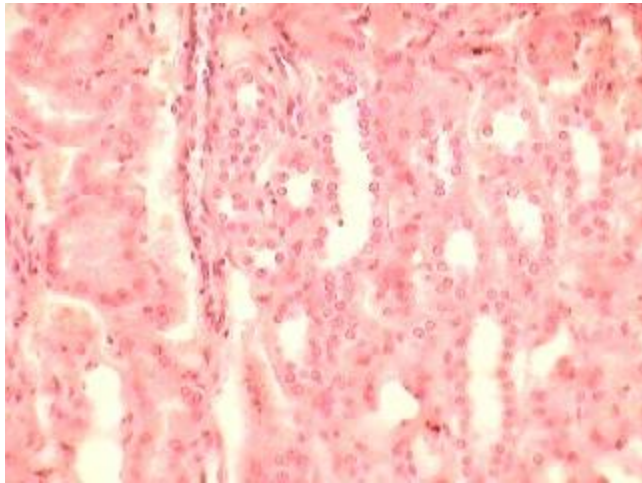
Question 2 Answer

Stratified Squamous Epithelium



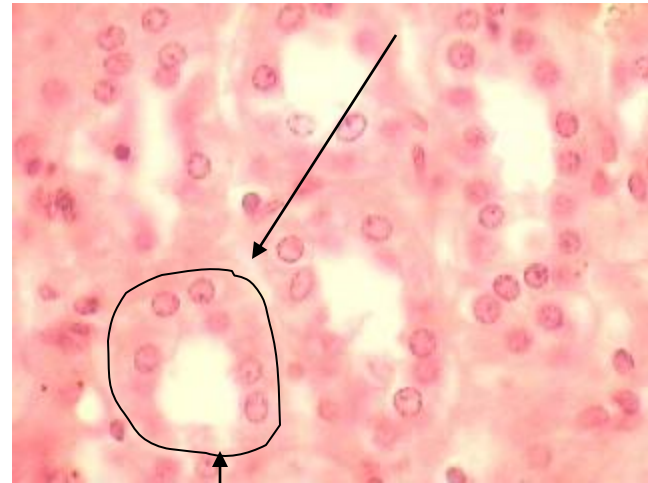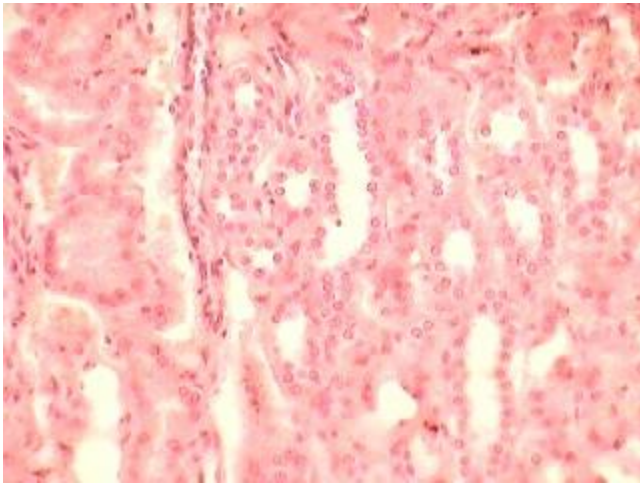
basement membrane

Question 3 – Name the tissue at the pointer.



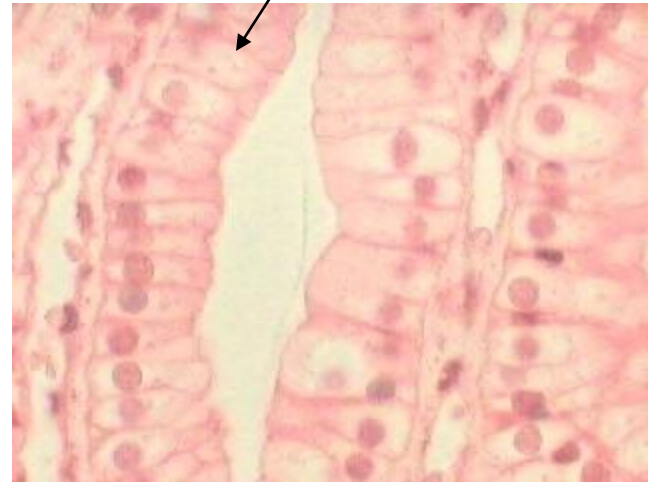
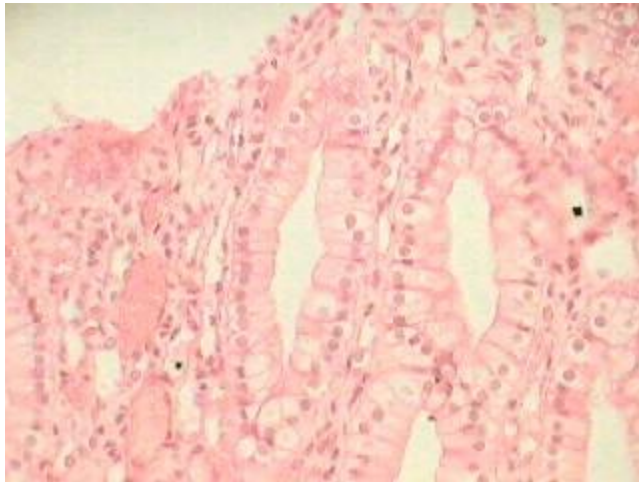
Question 3 Answer

Simple Cuboidal Epithelium



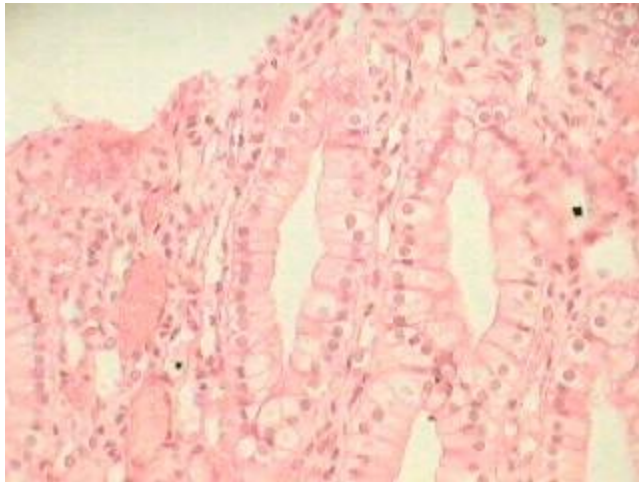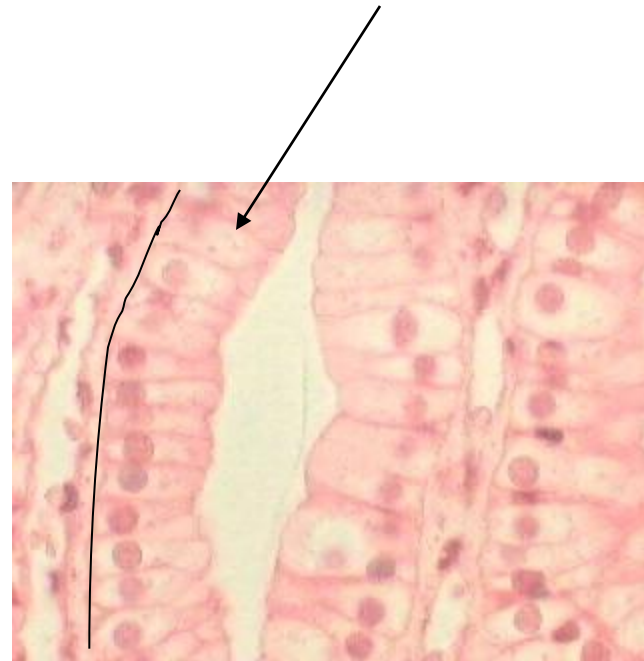
basement membrane

Question 4 – Name the tissue at the pointer.



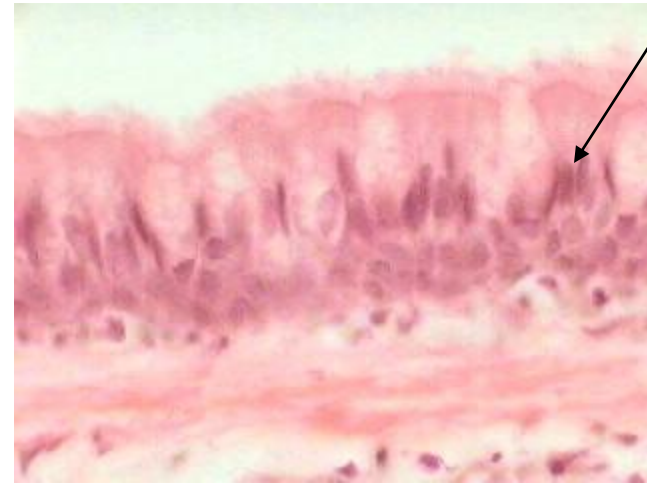
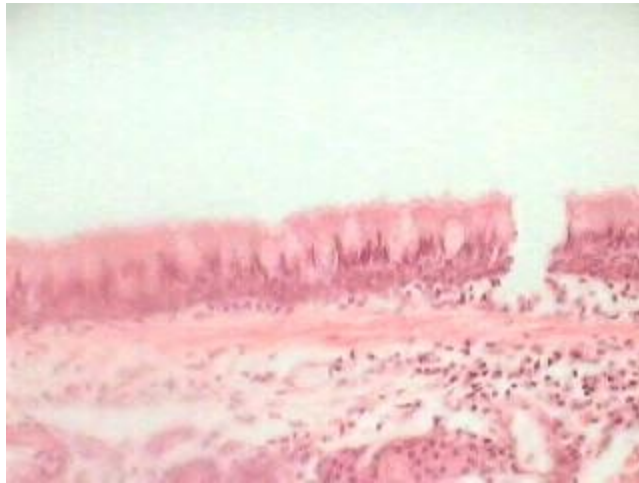Question 4 Answer

Simple Columnar Epithelium



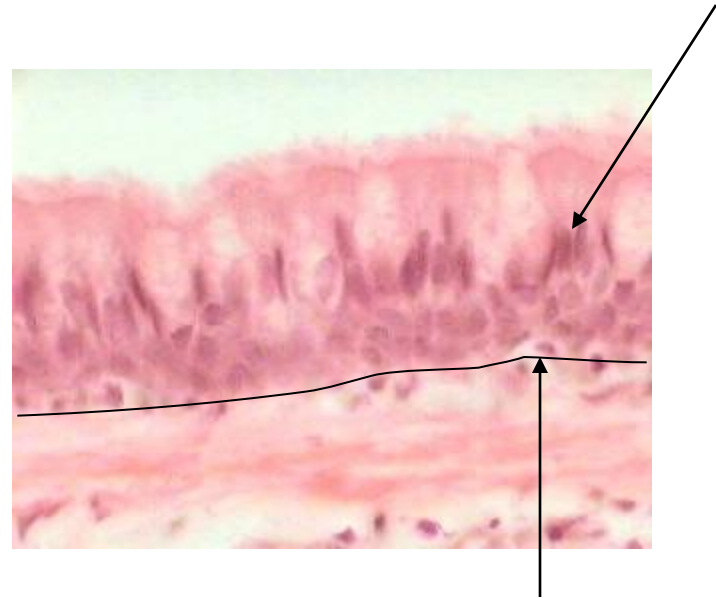
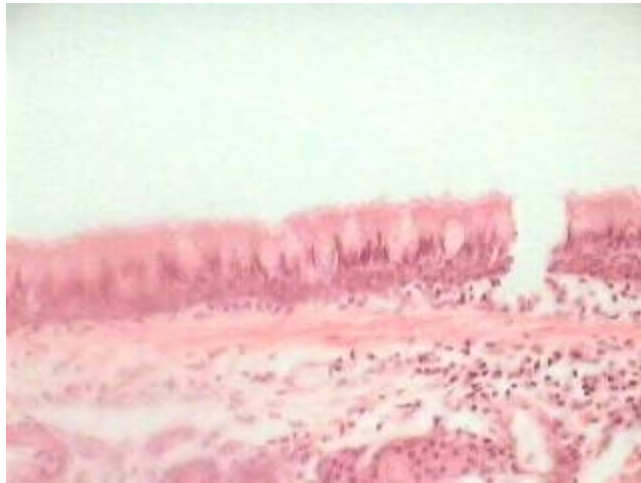basement membrane

Question 5 – Name the tissue at the pointer.



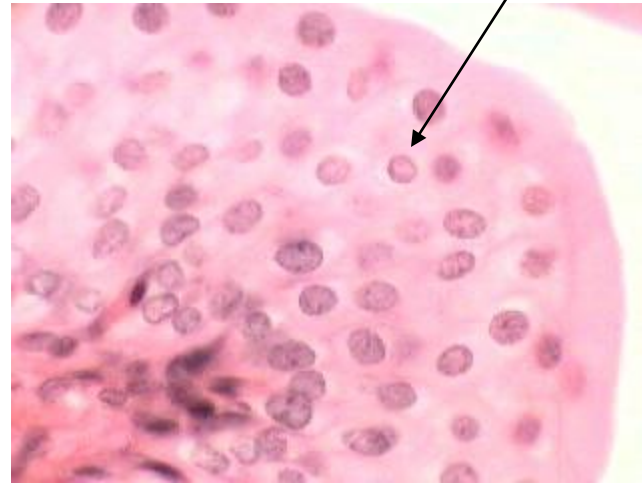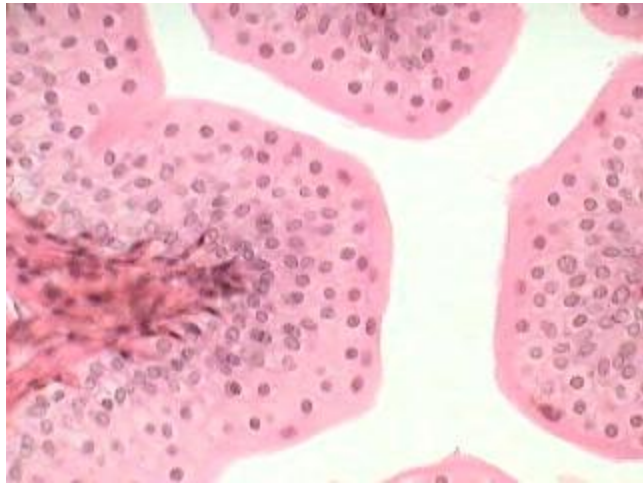
Question 5 Answer

Pseudostratified Columnar Epithelium



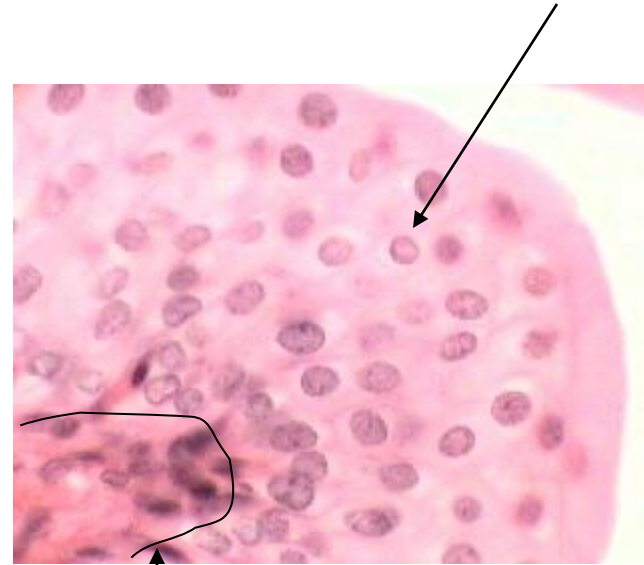
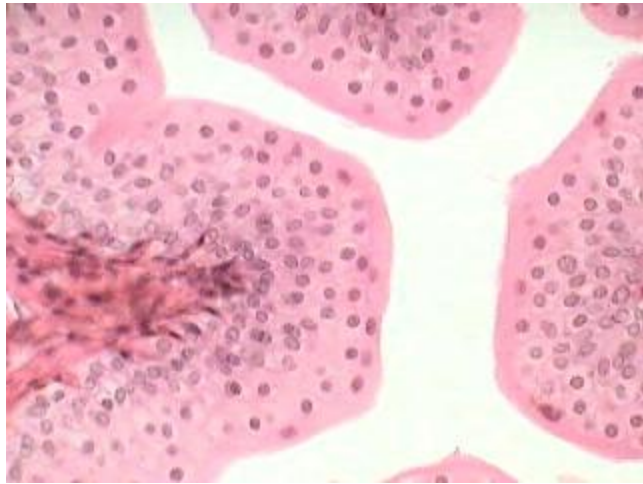
basement membrane

Question 6 – Name the tissue at the pointer.



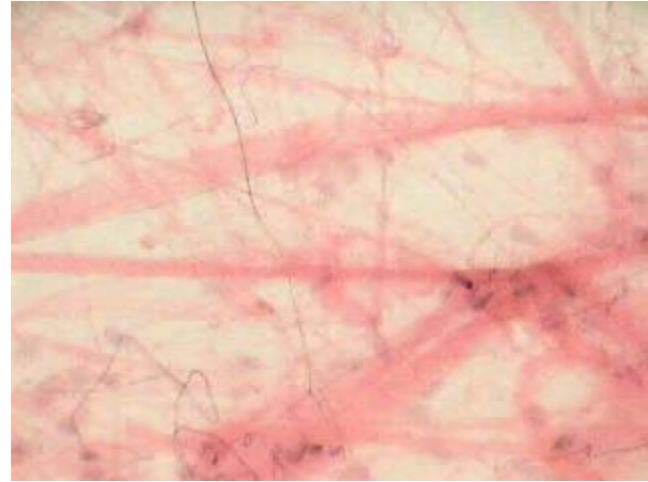
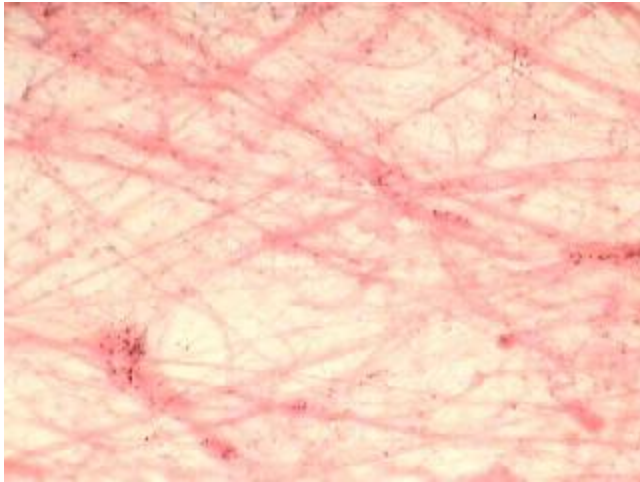
Question 6 Answer

Transitional Epithelium



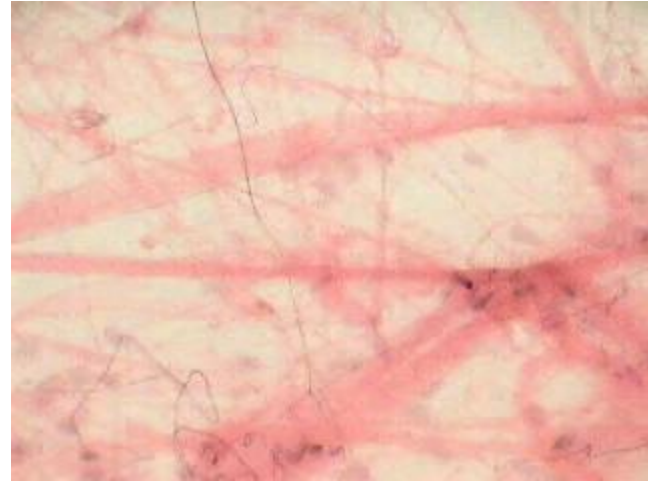
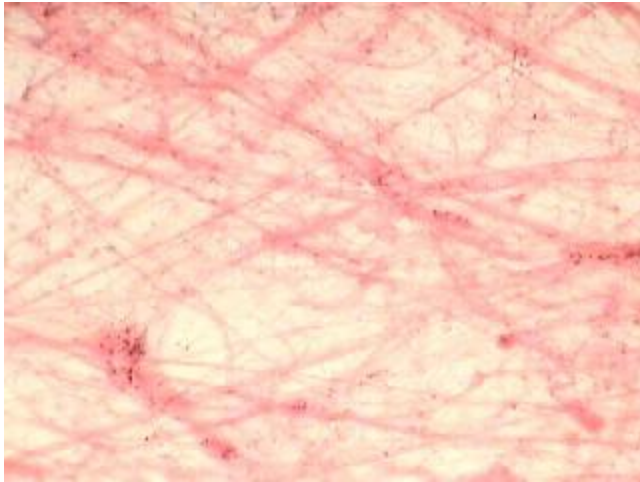
basement membrane

Question 7 – Name this tissue.

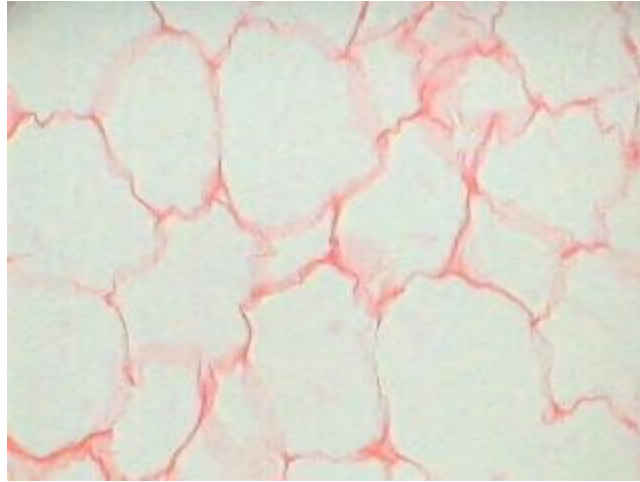


Question 7 Answer

Loose Areolar Connective Tissue

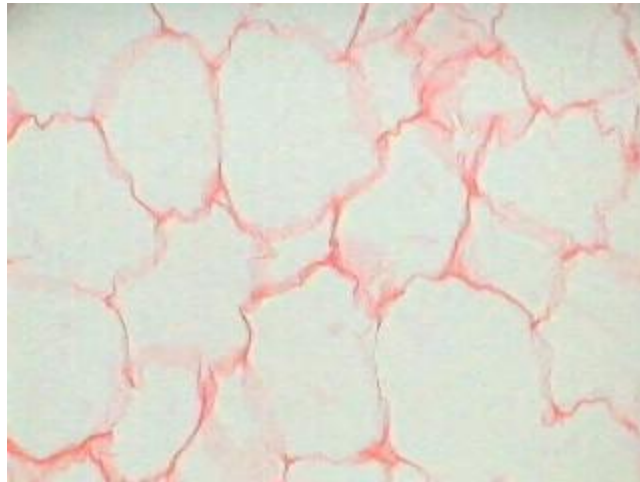


Question 8 – Name this tissue.

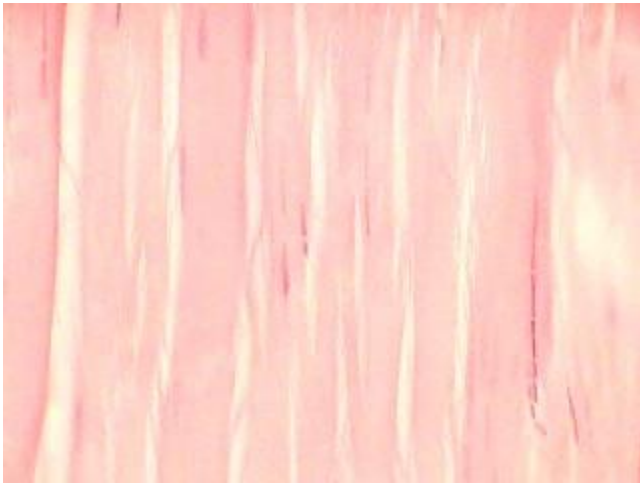


Question 8 Answer

Adipose Tissue

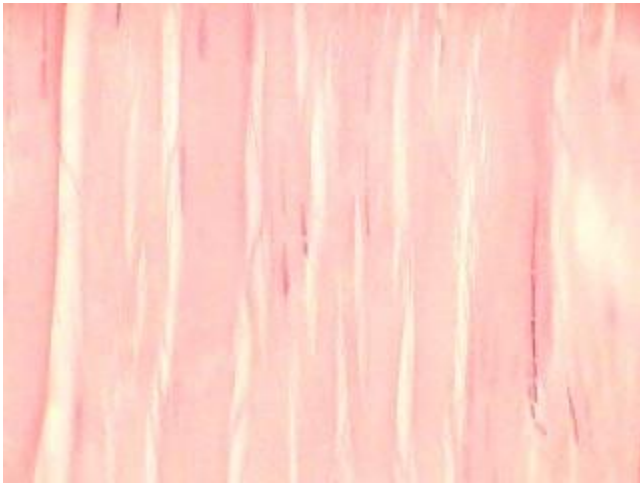


Question 9 – Name this tissue.

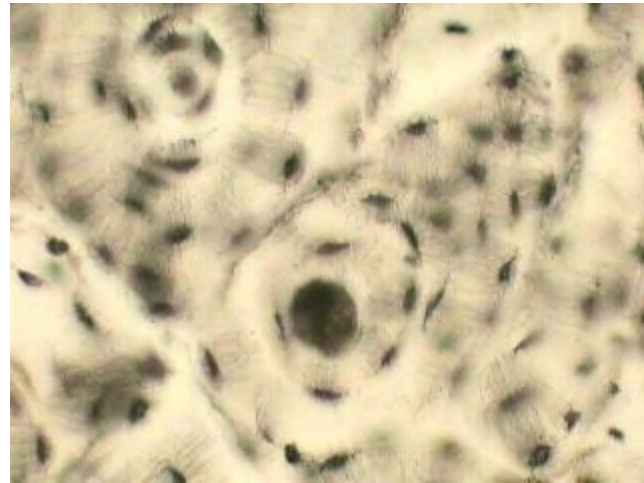
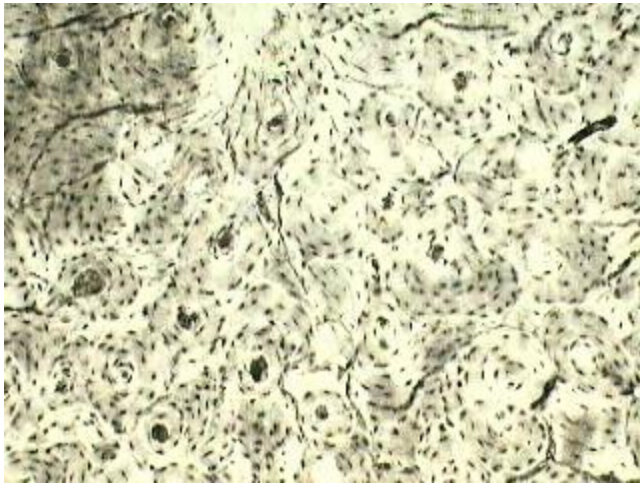


Question 9 Answer

Dense Regular Connective Tissue

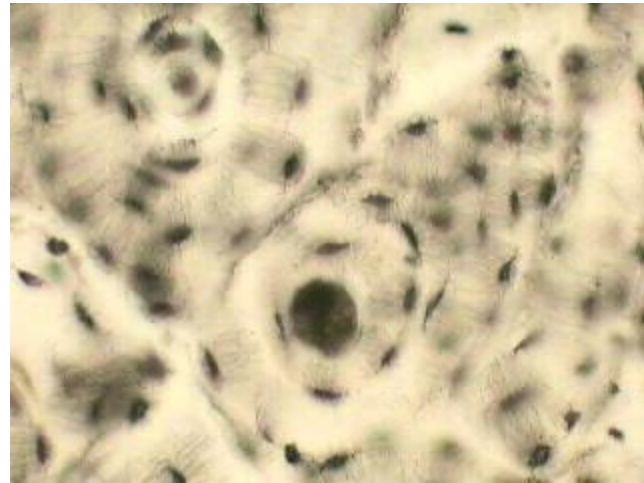
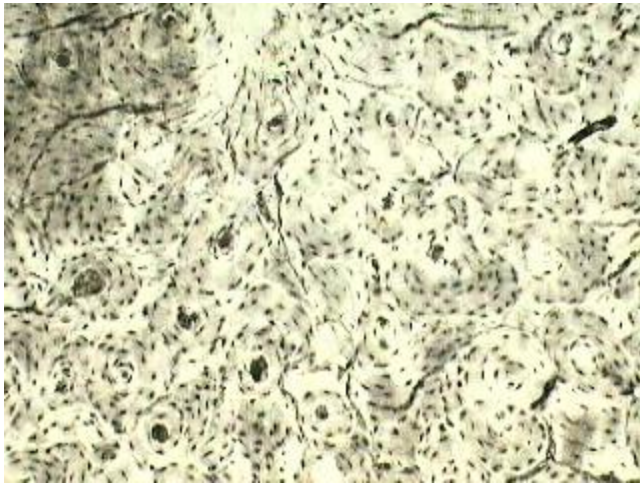


Question 10 – Name this tissue.

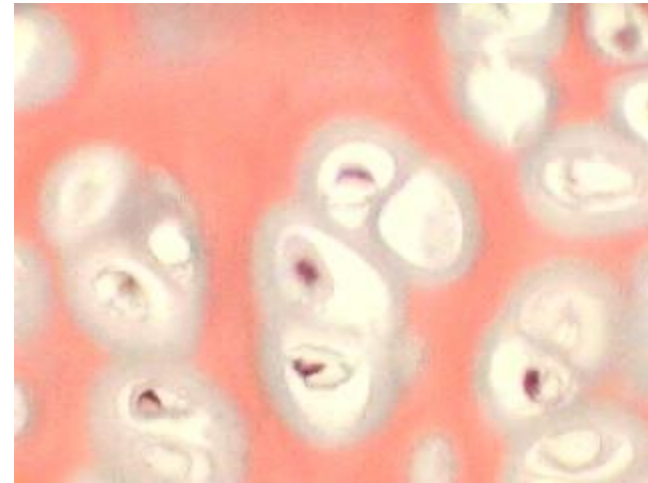
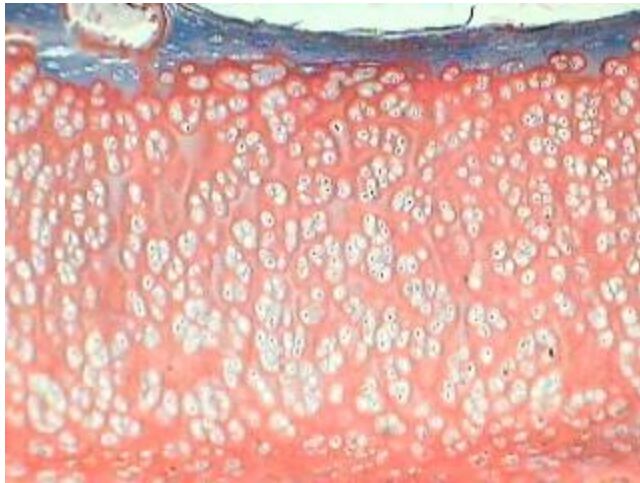


Question 10 Answer

Bone

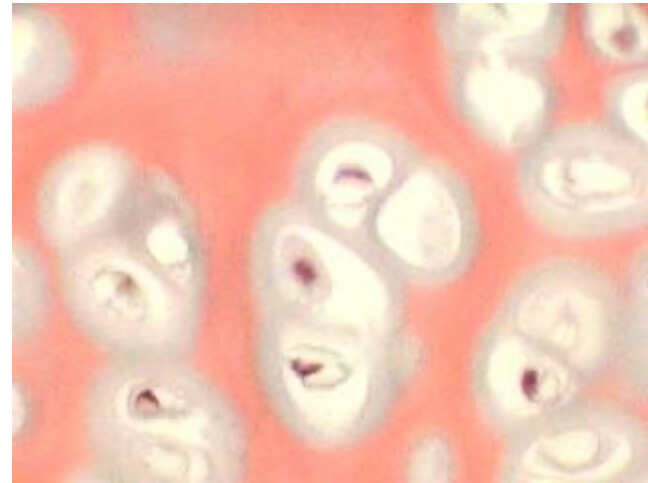
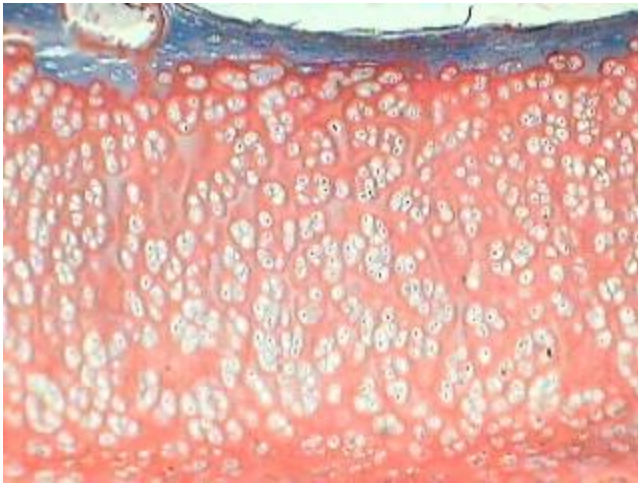


Question 11 – Name this tissue.





Question 11 Answer

Hyaline Cartilage





Question 12 – Name this tissue.

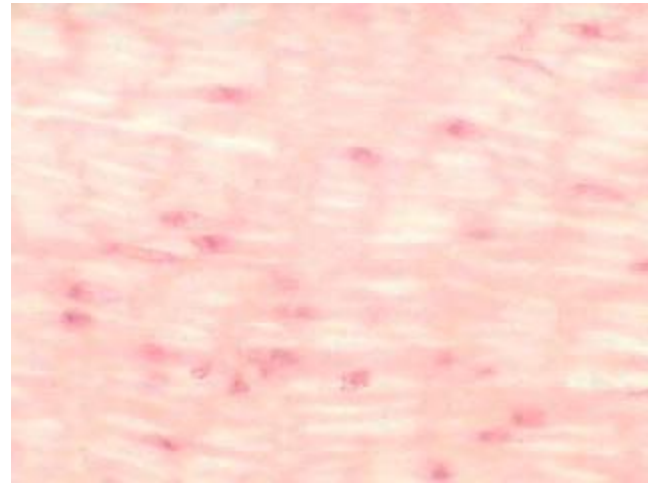
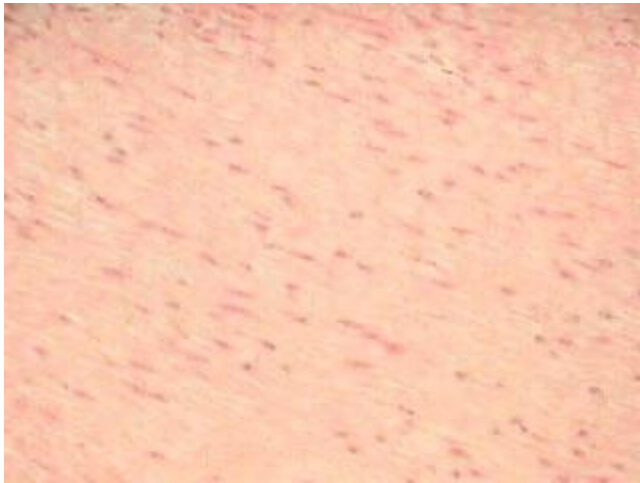

Question 12 Answer

Skeletal Muscle

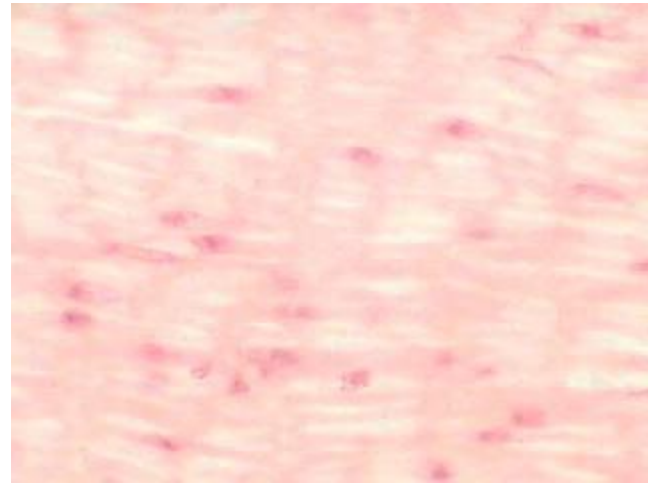


Question 13 – Name this tissue.

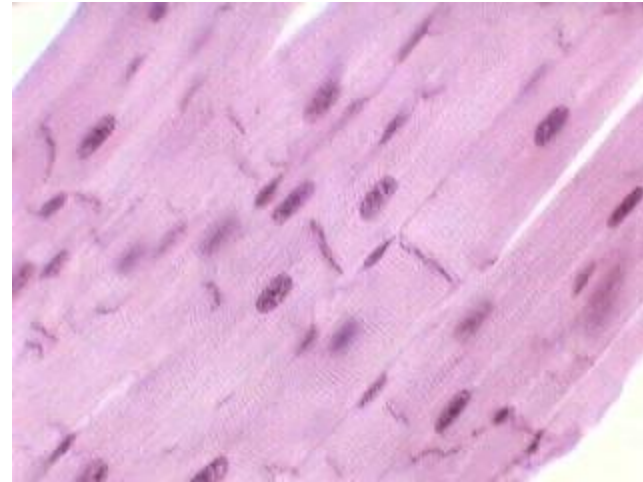
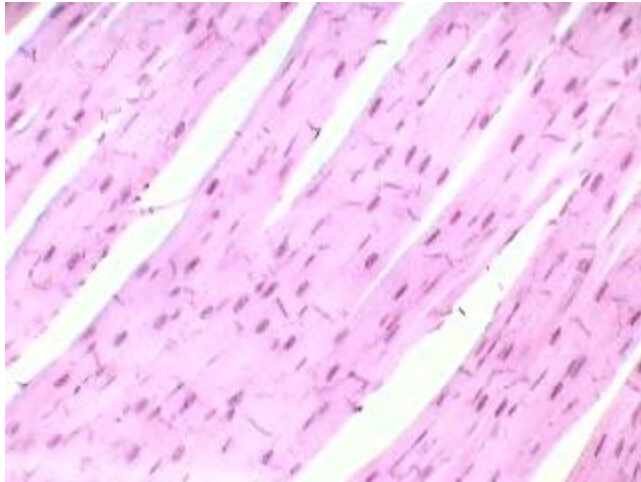


Question 13 Answer

Smooth Muscle

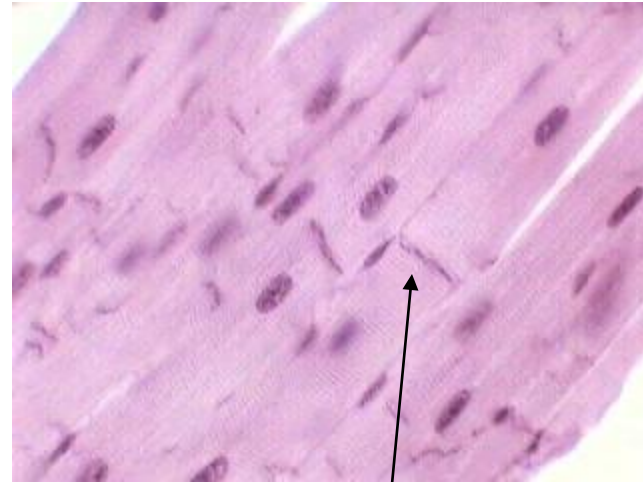
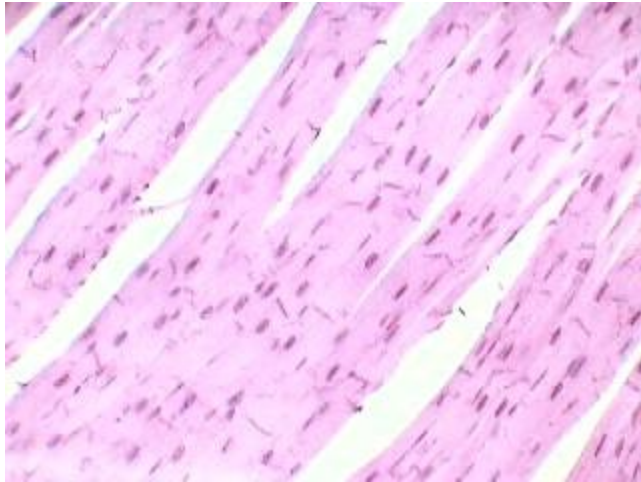


Question 14 – Name this tissue.



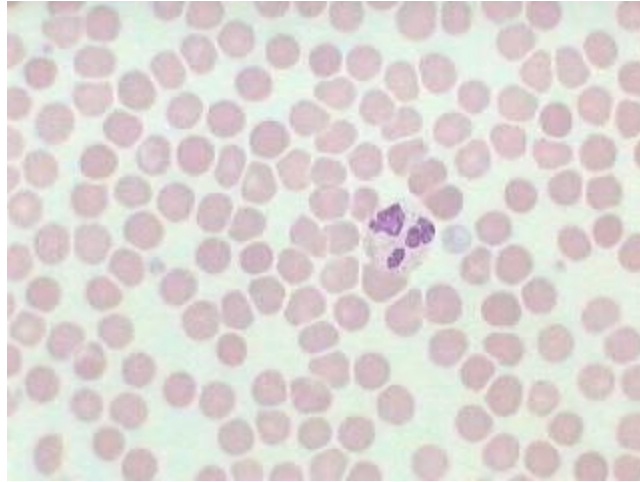
Question 14 Answer

Cardiac Muscle



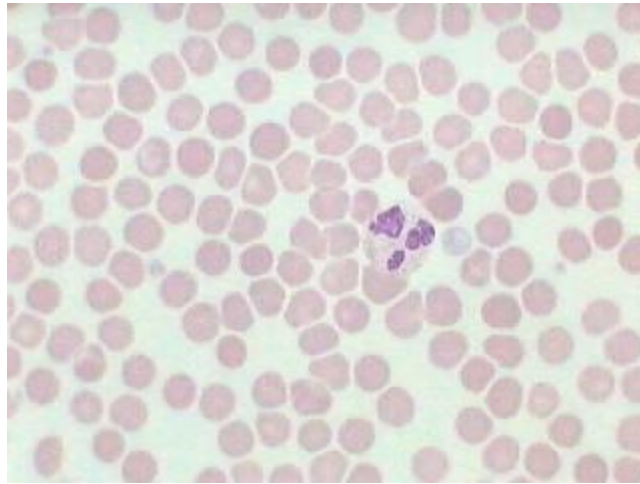
intercalated disk

Question 15 – Name this tissue.

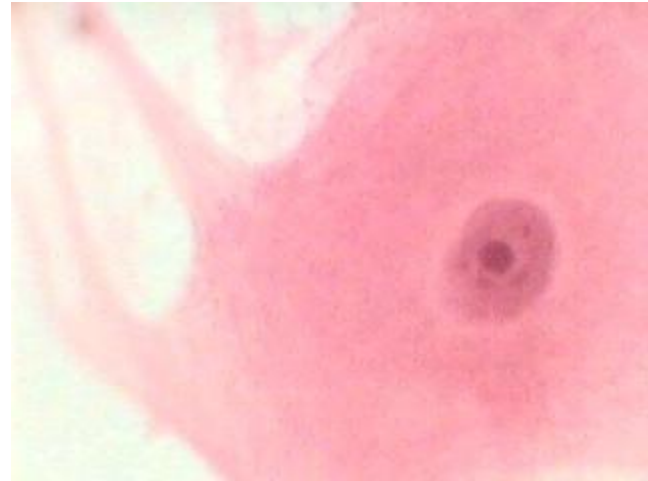
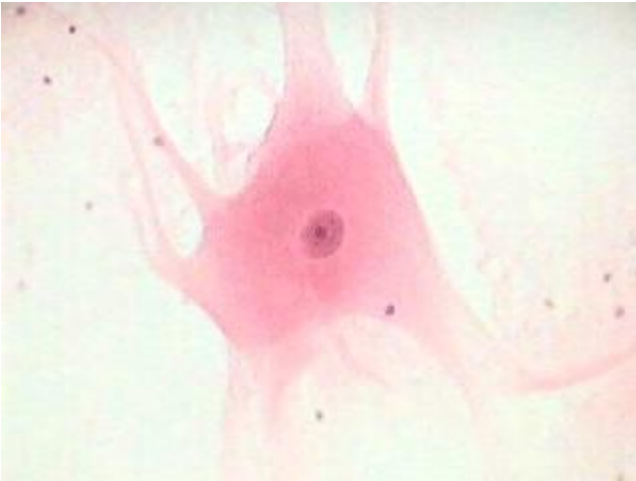

Question 15 Answer

Blood

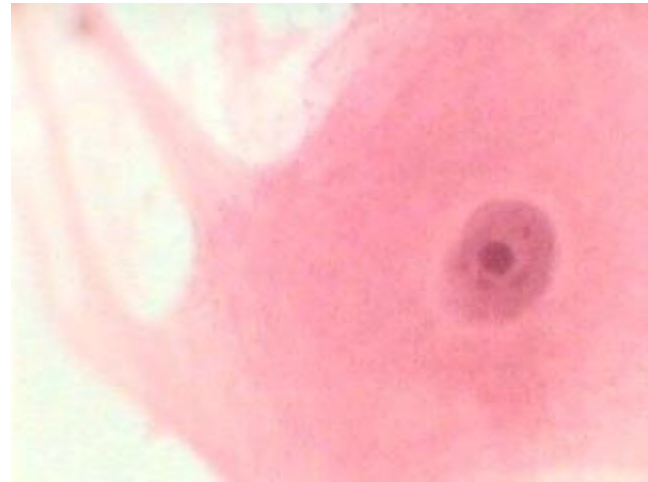
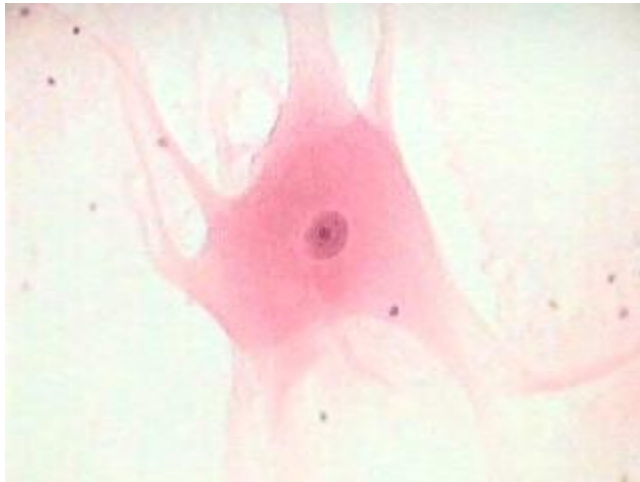

Question 16 – Name this tissue.



Question 16 Answer

Nervous Tissue or Motor Neuron



The End

- How did you do?
 - Use your results to direct your study.
-